

EFFECT OF HIGH INTENSITY FOCUSED ULTRASOUND (HIFU) ON HUMAN PROSTATE CANCER

Michael Marberger, M.D., Martin Susani M.D., Stephan Madesbacher, M.D.,
Christian Kratzik, M.D., Reiner Simak, M.D. Department of Urology, University of Vienna, Austria

ABSTRACT

Non-surgical. Loco-regional therapy of prostate cancer (PC) has been previously performed by irradiation and cryosurgery. Both technologies have significant drawbacks, such as lack of control, side effects and invasiveness. Recently high intensity focused ultrasound (HIFU) has been established as a highly effective means of inducing contact and irradiation free intraprostatic coagulative necrosis. In a phase I study, we determined the histological impact of transrectal HIFU on the prostates of 38 patients with localized PC, who underwent subsequent radical prostatectomy. Mapping of coagulative necrosis was possible in all prostates in good correlation to the computer defined target zone. Histological and ultrastructural analyses revealed complete necrosis (point of no return) within this tissue segment. The transmission of the ultrasound beam was comparable in benign and PC tissue. Subsequently we targeted HIFU ultrasound guided to clearly visible (hypoechoic), circumscribed (1.2±0.9cm), histologically proven PC (n=8) and correlated the HIFU lesion to histology after radical prostatectomy. In 2 cases we were able to completely destroy PC with HIFU. In the other 38-77% of the cancer was destroyed but there were marginal residuals of PC. Tumor margins as defined by hypoechogenicity at transrectal ultrasonography and histology obviously correlate poorly. The tumor bearing lobe. 4 patients with T2 PC unwilling to undergo radical surgery or radiotherapy have been treated with this technique since. There was virtually no postoperative morbidity. Follow-up biopsies were negative in tow patients 2 and 6 months later; in the third patient there were positive and this area was retreated with HIFU without additional toxicity. Although these data permit no definitive conclusion on the efficacy of this approach, it seems to achieve local tumor destruction and could therefore ultimately become a minimally invasive therapeutic option.

TECHNOLOGY

Ultrasound in the 4MHz range can be focused to site intensities of 1260 to 2200 W/cm². This results in a sharp increase of temperatures to 80-100°C (Figure 1), which causes immediate, sharply delineated coagulative necrosis of all tissues within the focal region (Figure 2). Surrounding structures remain unharmed. By using transducers of 2.5-4.0cm focal length, which are inserted into the rectum, this technique can be applied to the prostate to obtain larger lesions, the transducer is moved under computer control (SONABLATE, Focus Surgery Inc., Milpitas, CA) (Figure 3), as the same transducer is also used for imaging, the procedure is performed under the ultrasound guidance. Clinical experience with transrectal HIFU in >200 patients with BPH has proven the technique to be safe, minimally invasive and effective.

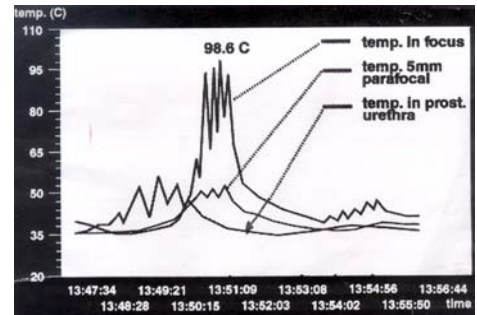


FIGURE 1

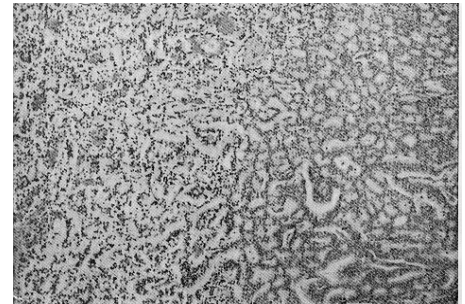


FIGURE 2

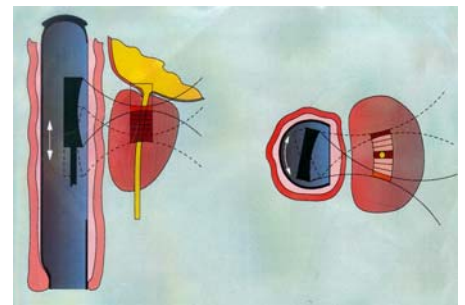


FIGURE 3

MATERIALS AND METHODS

There is no valid animal model. Patients with localized cancer of the prostate were subjected to a HIFU marker lesion immediately prior to radical prostatectomy. The lesion was analyzed histologically from whole mount sections of the specimen using planimetry and 3-dimensional reconstruction.

Patients with palpable, biopsy-proven T2A cancer of the prostate, which was discernible at transrectal ultrasonography, were "treated" with transrectal HIFU immediately prior to radical prostatectomy. The hypoechoic area was targeted, specimens were evaluated as in Color Plate A.

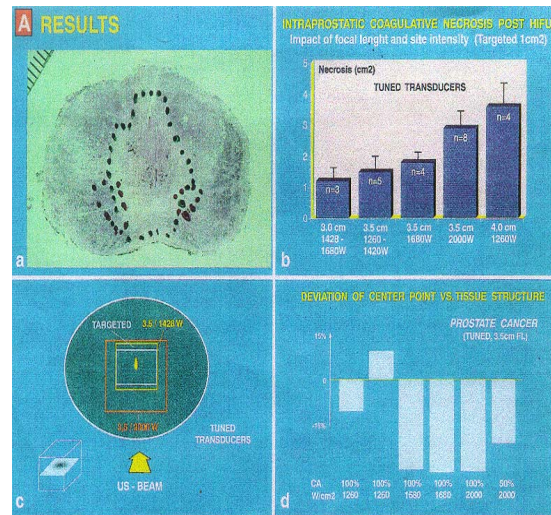
Patients with cancer as in Color Plate B, but unfit/unwilling for radical prostatectomy/radiotherapy, were "treated" prospectively with transrectal HIFU. The entire tumor-bearing lobe was ablated. Follow-up is with PSA, TRUS and biopsy every 3 months. HIFU retreatment is planned with a positive biopsy.

OBJECTIVE

To evaluate a possible role of transrectal HIFU in the management of localized prostate cancer.

Conclusion 1 (See Color Plate: A-Results)

- Sharply delineated, coagulative necrosis of predictable size and location is routinely obtained (a); histologically no evidence for cavitation.
- The surrounding structures appear macro- and microscopically unchanged; the rectum is unaffected.
- The lesion size increases multifold with site intensity and focal length of transducer (b). A lesion obtained with 2000W/cm² - 10 fold larger than with 1460W/cm² with the same transducer (c).
- The lesion moves towards transducer with higher site intensities (c) and longer focal length.
- The tissue structure respective TU. Grade is of minor importance for lesion size and location (d).



Conclusion 2 (See Color Plate: B-Results)

- Localized prostate cancer can be destroyed with tranrectal HIFU.
- Transrectal ultrasonography is insufficient to delineate extent of cancer.
- Entire tumor-bearing lobe has to be ablated.

Conclusion 3 (See Color Plate: C-Results)

- Preliminary, experience suggests transrectal HIFU may control localized prostate cancer with minimal morbidity (no complications, postop. Hospitalization 1-3 days).
- Major Attraction: Retreatment is possible without added toxicity to surrounding structures

